



PRESENTING CLINICAL SIGNS

DATE History: Murmur. Episodes of staring off into space. Multiple mammary tumors.

3/2/22 ECHOCARDIOGRAPHIC FINDINGS

2D, M-mode, and Doppler study.

PERFORMED BY

Dr. Meredith Swart

Left atrial size is normal. The mitral valve leaflets are mildly thickened and exhibit systolic prolapse. There is Doppler evidence of mitral regurgitation present. Left ventricular dimensions are normal. Left ventricular systolic function is normal. The aorta and aortic valve are normal. Right atrial and right ventricular dimensions are normal. The tricuspid valve is normal. The pulmonary artery and pulmonic valve are normal. No heartworms are visualized. No pericardial effusion or cardiac masses are seen.

INTERPRETED BY

Keith Blass, DVM,
MS, DACVIM
(Cardiology)

LA - 20.5 mm
LVIDd - 19.0 mm
LVIDs - 11.6 mm
FS - 38.9%

PATIENT

LVOT - 0.89 m/s
RVOT - 0.73 m/s

Sofia Loria

ASSESSMENT/RECOMMENDATIONS

Degenerative mitral valve disease

SPECIES

Canine

This examination demonstrates regurgitation of blood across Sofia's mitral valve resulting from degenerative valve disease. The hemodynamic effects of the regurgitation appear to be mild, as Sofia does not have secondary dilation of either of her left heart chambers. As such, Sofia's mitral valve disease appears to be well-compensated, and her current risk for the development of clinical signs secondary to it, such as coughing, exercise intolerance, syncope, and labored breathing, appears to be low.

BREED

Pomeranian

No reason for Sofia staring off into space is appreciated in this exam, though consideration can be given to the possible presence of an intermittent arrhythmia.

SEX

An ECG and/or Holter/event monitor may be warranted.

FI

No therapy is recommended based on this exam.

AGE

10 y

A recheck echocardiogram is recommended in 6 months to monitor for disease progression.

WEIGHT

6.9 lb

HOSPITAL NAME

Swart Veterinary
Imaging

REFERRING VET

Dr. Swart



DATE

3/2/22

PERFORMED BY

Dr. Meredith Swart

INTERPRETED BY

Keith Blass, DVM,
MS, DACVIM
(Cardiology)

PATIENT

Sofia Loria

SPECIES

Canine

BREED

Pomeranian

SEX

FI

AGE

10 y

WEIGHT

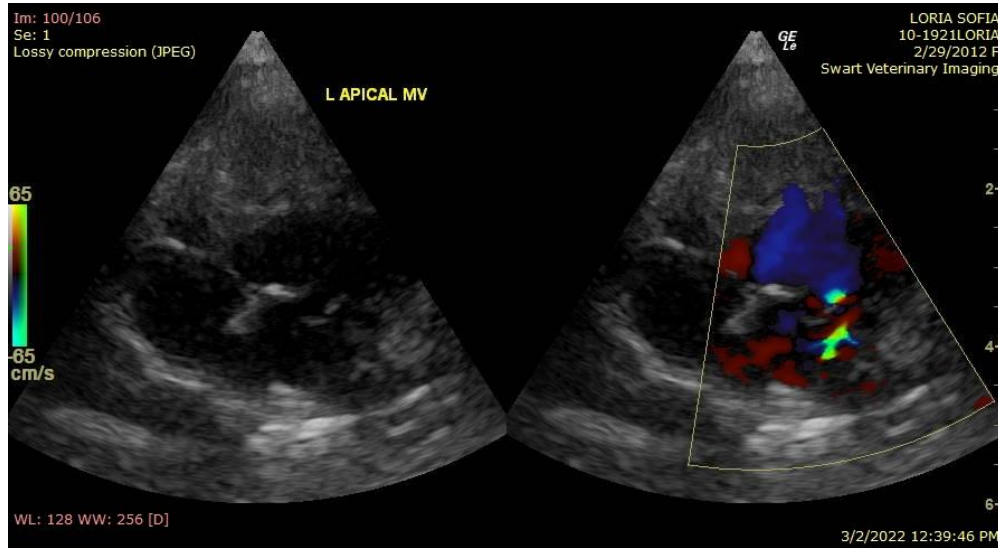
6.9 lb

HOSPITAL NAME

Swart Veterinary
Imaging

REFERRING VET

Dr. Swart



The information and recommendations provided are based on the images presented by the referring veterinarian. No evaluation can be communicated regarding pathology that was not visible in the image/video clips provided.

Thank you for this referral. If the clinical or image interpretation does not parallel your findings or if I can be of any further assistance please contact me.

Keith Blass, DVM, MS, DACVIM (Cardiology)
KeithBlass@gmail.com
631-804-5754